

RETROPERITONEAL LYMPHADENECTOMY IN STAGING AND TREATMENT

The Development of Nerve-Sparing Techniques

John P. Donohue, MD, and Richard S. Foster, MD

Two decades ago, the extended bilateral suprahilar retroperitoneal lymphadenectomy was described using special exposure techniques via the midline abdominal approach.⁴ This wide template of dissection (Fig. 1) encompassed all the known sites of lymphatic drainage within the retroperitoneum. The rationale behind this extensive procedure was that it provided the best guarantee of removing all microscopic deposits of infradiaphragmatic metastatic disease in an era when relapse was often fatal owing to poor chemotherapy rescue. Results from that period justified this intensive surgical approach in nonseminomas; the lower relapse rate combined with improved survival was better than prophylactic irradiation programs, the only other alternative treatment available at that time.

Since the mid-1960s, we have performed 2200 retroperitoneal lymph node dissection (RPLND) operations at the Indiana University Medical Center. It is against this background of experience that we have gradually but consistently modified our surgical techniques. The initial impetus for modifying the type of

operation we performed came from an improvement in our understanding of the specific sites of nodal metastases from testis cancer. Thus, the wide field of dissection in the suprahilar operation could be downscaled without jeopardizing its potential for accurate staging or therapeutic benefit if nodes were involved. The other reason for wishing to modify our operative approach was that surgical morbidity became a significant factor to be taken into consideration when effective chemotherapy became available for nonseminomatous testis cancer.⁸ In particular, both patients and surgeons alike focused on the loss of ejaculatory function as the principal area of concern because it invariably followed the standard bilateral lymphadenectomy.⁵ This article traces the historical development of RPLND, including the downscaling of resection templates and the subsequent development of nerve-sparing techniques. The technique of nerve-sparing modified RPLND is described in the manner that we perform these operations today. Arguments concerning the role of primary retroperitoneal lymphadenectomy and the choice between surgery,

From the Department of Urology, Indiana University Medical Center, Indianapolis, Indiana

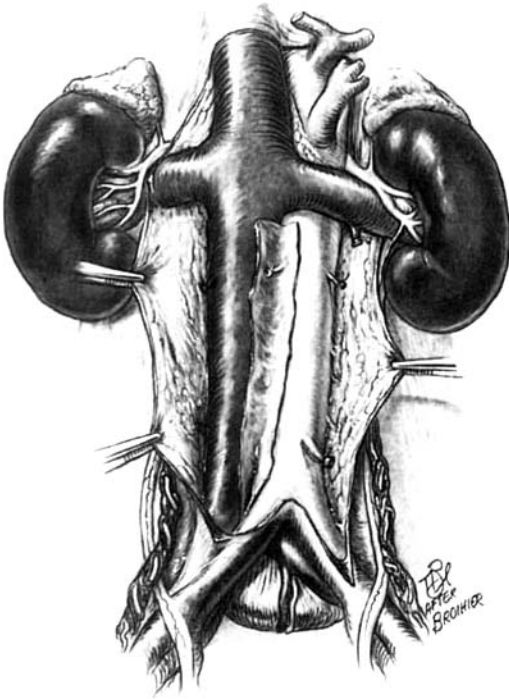


Figure 1. The wide template of resection in the traditional bilateral suprahilar dissection is well above the renal vasculature. From the technical viewpoint, note how the lymphatic tissues are split and then rolled off the great vessels.

surveillance, or primary chemotherapy as the most appropriate management options in stage I and II are beyond the scope of this article.

SEQUENTIAL MODIFICATIONS IN OPERATIVE TECHNIQUES

Our first modification to the traditional operation of bilateral suprahilar RPLND was omission of the suprahilar component of dissection. This reduction in the surgical template was considered appropriate when studies showed that the suprahilar lymph nodes were not a primary zone of metastatic spread in testis cancer unless there was gross involvement of the lower (infrahilar) para-aortic nodes.¹⁵ The safety of omitting a routine suprahilar dissection was confirmed by subsequent surgical series. In addition to the efficacy of the bilateral infrahilar approach, the operation gained popularity because it was technically less demanding than its pre-

decessor and operative time was also reduced.

Considering the time period involved, the bilateral infrahilar RPLND was a safe and effective tool in the urologist's armamentarium against low-stage cancer of the testis. The previous training for performing suprahilar dissections was not in vain because it became useful when operating for bulky disease in the postchemotherapy setting. The principal drawback of the bilateral infrahilar operation, however, related to its morbidity, especially the loss of ejaculatory function, which occurred in almost all cases.¹³ This direct complication of surgery became of increasing importance when new developments in radiology and serum markers made it possible to evaluate disease stage more accurately using noninvasive methods. Also, the dawning of the era of chemotherapy with the introduction of cisplatin made it possible to rescue patients with relapse reliably. With this new emphasis on the morbidity of treatment, there was growing pressure to reject primary surgery in favor of surveillance in early-stage nonseminomas, and this approach was adopted in several countries including the United Kingdom and Scandinavia. Meanwhile, surgical centers committed to RPLND further downscaled the boundaries of dissection in an effort to preserve postoperative ejaculation.^{6, 7, 14} Resulting modified unilateral templates (Fig. 2) were based on prior knowledge of the zones of metastatic spread and a general recognition that the critical region in preserving ejaculation was the para-aortic tissues below the level of the inferior mesenteric artery.^{11, 16} This region contains the lumbar sympathetic chain and the postganglionic fibers from the ganglia L2 to L4 (Fig. 3). Studies of male sexual dysfunction following RPLND pointed to the injury of the sympathetic nerves as the key to this problem and further dissection work, both at Indiana University and elsewhere, elucidated the course of the sympathetic postganglionic nerves.^{3, 12} Traveling in the para-aortic tissues, these fibers decussate to form the so-called *hypogastric plexus*. The terminal nerve trunks from this plexus pass inferiorly to terminate in the ejaculatory apparatus of the seminal vesicles and ampullary portion of the vas.

These modified unilateral templates preserving sympathetic fibers were associated with greater preservation of ejaculation in the range of 90%. This reduction in surgical morbidity has led to the adoption of unilateral

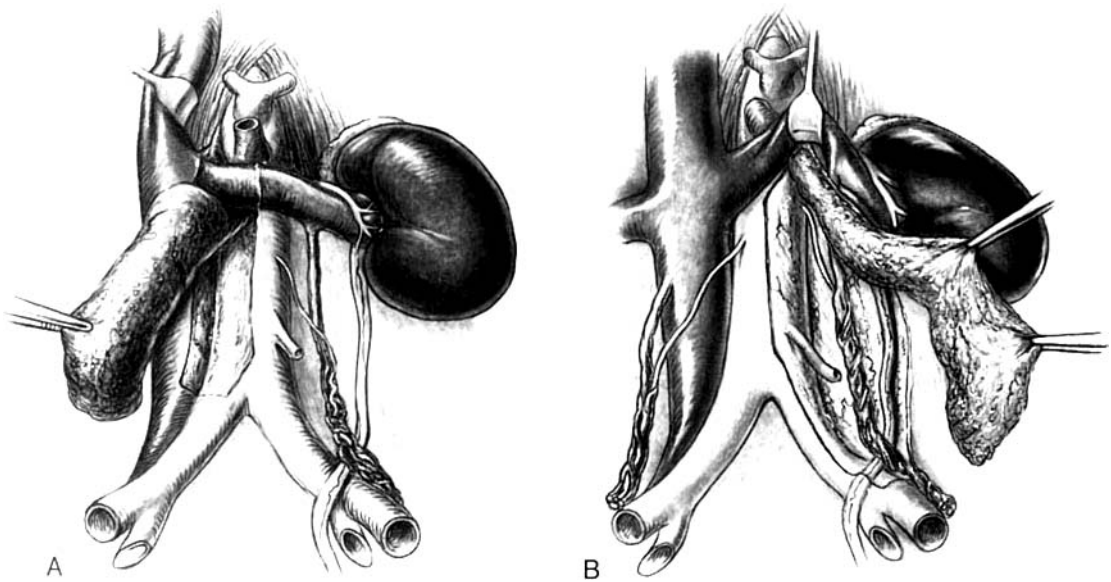


Figure 2. A, The right sided modified unilateral template in which the interaortocaval lymph nodes are included while the left para-aortic lymphatic tissue remains undisturbed. B, The left sided modified unilateral template includes the upper interaortocaval group and left para-aortic lymphatic tissues. The lower right para-aortic region remains undisturbed.

modified RPLND by most surgical centers treating cancer of the testis. The benefits of a modified unilateral approach in combining a complete cancer operation with a good chance of ejaculatory preservation was a significant development in the management of early-stage disease. This was particularly cogent in view of the increasing number of relapse rates reported by centers using surveillance only.^{9, 10}

The modified template significantly reduced surgical morbidity but it was felt that a more proactive role for the surgeon was indicated because the means of preserving the nerves in the modified unilateral operation simply relied on their exclusion from the dissected template. Nonetheless, in 10% to 40% of cases the nerves are damaged using the modified template and, therefore, as long ago as 1978 we began our first efforts to identify prospectively sympathetic fibers in the course of RPLND. It was our belief that if dissection of the sympathetic fibers was done before lymphadenectomy then preservation of ejaculation might be preserved in virtually all RPLND patients. In carefully selected patients with low risk of recurrent disease we gradually introduced a nerve-sparing modification when performing a modified unilateral proce-

dure. By 1984 we were convinced that some patients could have their postganglionic fibers identified and preserved during the course of an effective staging lymphadenectomy. The intermingling of sympathetic fibers with the lymphatic tissues is such that their preservation may add slightly to operation time. We find that a nerve-sparing procedure, however, is not only feasible but removes the only remaining morbidity of primary RPLND.

THE SURGICAL TECHNIQUE OF NERVE-SPARING MODIFIED RPLND

As described previously, the templates for resection are different for right- and left-sided testis tumors. Therefore, our operative approach varies according to the side of initial testis primary.

Nerve-Sparing Modified RPLND for Right-Sided Tumors

The retroperitoneum is exposed by incising the root of the small bowel from the cecum to the ligament of Treitz. The small bowel

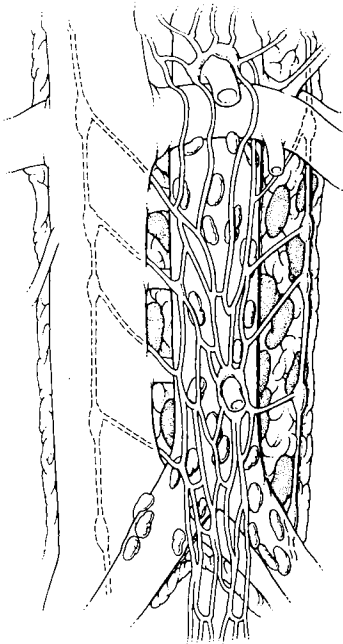


Figure 3. A schematic diagram of the lumbar sympathetic nervous system and its relation to the great vessel. Note the sympathetic ganglia L2–L4, the hypogastric plexus and terminal nerve trunks.

mesentery is separated from the anterior aspect of Gerota's fascia giving access to the great vessels. The gonadal veins are clearly visible. This exposure is maintained by the use of laparotomy pads and a large ring retractor.

Sometimes the terminal nerve trunks of the sympathetic hypogastric plexus are visible in the preaortic area near the origin of the right iliac artery, but in most patients these delicate strands are obscured by fat. Therefore, it is usually simplest to begin dissecting in the traditional manner at the level of the renal vein. The lymphatics on the anterior aspect of the left renal vein are divided; this dissection is carried medially and thence in a caudal direction to the crossing of the external iliac artery. Dissecting in the anterior midline of the cava (12 o'clock) avoids damaging the nerve roots where they emerge medially from underneath the cava toward the aorta (Fig. 4). This anterior division of the lymphatics over the great vessels is called *the anterior split*. The subsequent dissection of this package off the great vessels medially and laterally is called *the roll technique*, hence the term *split and roll*. Using this technique, one can readily identify

the nerve roots of L1, L2, and L3 in the packet of tissue that is rolled medially off the cava. A plastic vessel loop is placed around each nerve branch to make it more obvious and to permit gentle traction during subsequent dissection. Once the roots of L1, L2, and L3 are taped it is a simple matter to dissect distally and connect with the decussation of fibers that form the distal trunks of the hypogastric plexus as they pass anterior to the iliac vessels and down into the pelvis. In the course of this dissection, the anterior set of interaortocaval lymph nodes can be resected off the nerve roots, which lie posteriorly. The more substantial and difficult portion of this dissection follows and this involves mobilization of the remaining interaortocaval lymph nodes that lie posterior to the nerve roots. These posterior interaortocaval nodes lie in a sulcus bounded by the nerve roots laterally, the anterior spinous ligaments and lumbar vessels posteriorly, and the aorta medially. This package is delivered by sharp and blunt dissection from the overlying nerve roots, which are gently elevated in the vessel loops. This part of the dissection can be most tedious if the prepared nerve roots are to be preserved. Major lymphatics are secured by clips, especially distally and those against the posterior body wall. The cephalad limit of the dissection is the right renal artery. The L2 to L4 nerve roots lie inferior to the renal artery but care must be taken when squaring out at the apex of the dissection so as not to catch the L1 nerve root as it passes to its ganglion just above and posterior to the renal artery. Ultimately, the interaortocaval lymph node package is drawn out from under the nerve roots. Usually the specimen is removed en bloc, but sometimes this is difficult and nodal tissue must be removed in segments so as to preserve the nerves. There is a significant amount of nodal tissue between the aorta and nerve trunks along the posterior body wall and it may be necessary to divide the lumbar vessels during the course of removing these nodes. The right para-aortic sulcus is now clear and one can see the anterior spinous ligaments, aorta, and nerve roots cleanly dissected.

The right-sided modified dissection is virtually complete, having removed the interaortocaval node group. The name *interaortocaval* distinguishes these nodes from those on the opposite side of the vena cava (the right paracaval group). This latter group are rarely involved in primary testis tumors and are not of

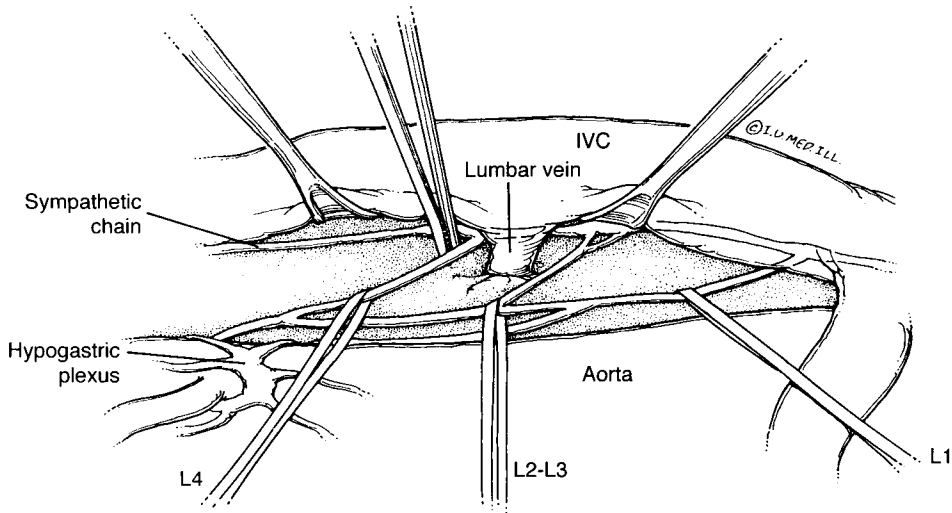


Figure 4. The right postganglionic fibers L1–L4 arise from the right sympathetic trunk dorsal to the cava, emerge into the interaortocaval and preaortic area, where they come in contact with splanchnic fibers in larger trunks. These are prospectively identified and isolated before lymphadenectomy.

paramount importance when doing a nerve-sparing operation. They are easily stripped off the vena cava and the posterior body wall, however, as a separate package. Again, care is taken to preserve the sympathetic chain and the branches of the genitofemoral and ilioinguinal nerve distally.

The interaortocaval node group (right para-aortic) is the central core of the modified template for right-sided tumors. The distal trunks below the inferior mesenteric artery and the contralateral L1 to L3 nerve roots are unlikely to be injured in such modified dissections if the zone of resection is limited to these interaortocaval parameters already mentioned. Therefore, even without ipsilateral nerve sparing, most patients should ejaculate when given a unilateral RPLND on this modified template.

Following dissection, the retroperitoneum is inspected and lymphatic leaks are clipped. The root of the small bowel is reapproximated with chromic catgut and the abdomen is closed without external drainage.

Nerve-Sparing RPLND for Left-Sided Primary Tumors

As previously explained, the template for resection is different in left-sided primary tumors and we use an alternative method for exposing the retroperitoneum whereby the

root of the small bowel is left intact. Instead, the left colon is elevated by dividing the left mesocolon from the level of the sigmoid up to and including the lienocolic ligament. The mesentery of the colon is separated from the underlying Gerota's fascia revealing the gonadal vein and great vessels. Retraction is set and the gonadal vein, which traverses the field, is divided where it enters the left renal vein. This exposes the underlying ureter, which forms the lateral boundary of the dissection template.

The initial step in a left-sided nerve-sparing technique is exposure of the lumbar sympathetic chain by dissecting posterolateral to the aorta. The L1 to L3 nerve roots are easily identified as they course medial and inferior, decussating with contralateral sympathetic branches and splanchnic sympathetic fibers, which course anterior to the aorta (Fig. 5). Occasionally, the nerve roots are apparent initially when exposing the retroperitoneum. If so, they can be taped and dissected with the sympathetic chain and the ganglia can then be identified by dissecting along the nerve roots themselves. In either case, with the sympathetic chain and nerve roots identified the anterior set of nodes is easily dissected off them. These nodes are few in number compared with the posterior group, which is isolated from the overlying nerve roots using the same technique as described for right-sided primaries (Fig. 6). The nerve roots are

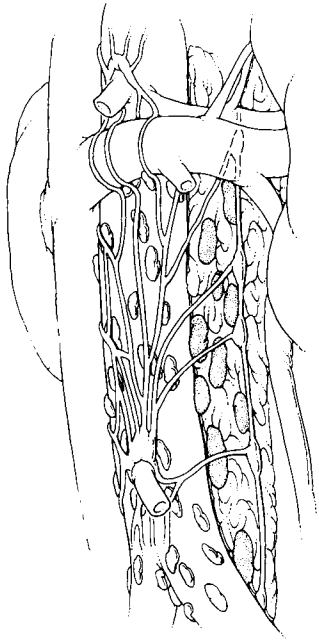


Figure 5. The left sympathetic fibers from the L1–L4 ganglia of the sympathetic chain dorsal and left of the aorta join the preaortic decussation of nerve trunks, just as their right sided (L1–L4) counterparts.

dissected to permit their elevation of the nodal package lying in the sulcus bounded by the aorta medially, the spinous ligaments posteriorly, and the nerve roots themselves, which course ventrally over them. A combination of blunt and sharp dissection is useful. Again, it is critical not to incorporate inadvertently the nerve roots in the lymph node specimen when squaring off the package superiorly. Also, care should be taken to elevate the left renal vein and divide any lumbar vessels

that drain into it to optimize exposure at the cephalad margin of the node package.

The left renal artery is the upper limit of dissection and the L1 to L3 nerve roots and the sympathetic chain course below this level. The node package can be dissected off the aorta with relative safety by keeping tension on the nerve roots in their plastic loops. The origin of the spermatic artery is divided and separated from the node package. As on the right, the interaortocaval nodes are drawn out from under the nerve roots while the lymphatic connections are clipped as they are encountered. Once this has been accomplished, the nerve-sparing left-sided template is complete and the mesentery of the colon is reapproximated prior to closure.

THE RESULTS OF NERVE-SPARING MODIFIED RPLND

Of 2200 RPLND operations performed at Indiana University Medical Center over the past 25 years, 483 patients have had primary RPLND using the nerve-sparing technique. Four hundred and two (83%) have had continuous adequate follow-up and responded to a survey. All the respondents claim normal ejaculation. Of the fertility survey, 98 have attempted pregnancy and 82 (84%) have been successful. Therefore, it is fair to say that ejaculation is reliably preserved by nerve-sparing RPLND and their fertility for the most part is preserved.

Of interest, of these 483 clinical stage I cases selected for ipsilateral (prospective) nerve-sparing RPLND, 359 (74%) were pathologic stage I but 124 (26%) were pathologic stage II. This underscores the insensitivity of clinical

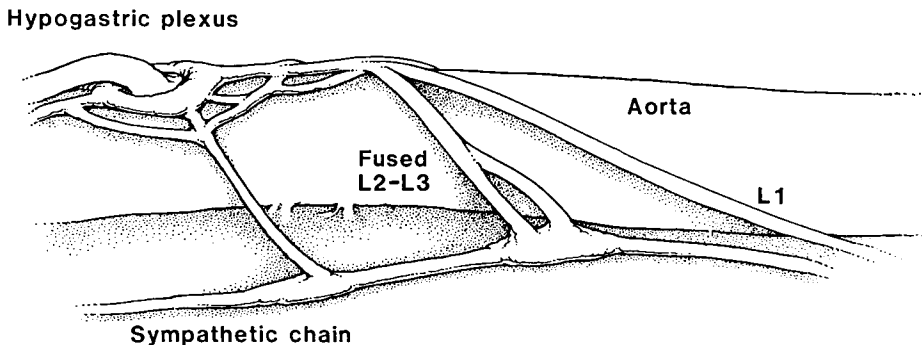


Figure 6. The left sided nerve sparing technique after clearance of the posterior set of lymph nodes. The ganglia of L2 and L3 may be fused or juxtaposed.

staging. There were only three proved retroperitoneal recurrences, two within the surgical template (0.4%) and one outside the surgical template. There were two deaths and eight are being treated for distant relapse. Therefore, the survival is 99.6% in our clinical stage I group.

POSTCHEMOTHERAPY NERVE-SPARING RPLND

Between March, 1988 and January, 1995, we reviewed 472 cases that underwent postchemotherapy RPLND here at Indiana University Medical Center. In 93 (19.7%) prospective nerve-sparing techniques were utilized. Two patients died within 6 months of postchemotherapy RPLND as a result of metastatic disease outside the retroperitoneum and ejaculatory status was not established. In 10 cases we were unable to determine this because of incomplete follow-up. The remaining 81 patients have been followed. Seventy-seven percent of these patients report normal ejaculation. None of these had a retroperitoneal recurrence of tumor. Eleven have achieved pregnancy and eight completed uneventful full-term delivery. Therefore, nerve-sparing postchemotherapy RPLND can preserve fertility potential without compromising patients in terms of relapse or survival.

THE CONTRIBUTION OF NERVE-SPARING MODIFIED RPLND

The traditional aim of cancer surgery has been to achieve radical removal of the primary tumor with its regional zone of lymphatic drainage. As such, radical surgery offers the best chance of preventing a local recurrence and, if nodes are positive, then it is hoped that treatment has been early enough to prevent further more distal relapse. This approach has long been known to produce considerable functional morbidity, however, and in urologic oncology today more emphasis is therefore put on combining good quality of life with the established concept of total tumor clearance.

Clearly, the ideal for patients with clinical stage I cancer of the testis is to identify those who in fact have microscopic nodal disease so they can be treated expediently. Currently, the most accurate way to achieve this aim is by RPLND. It can be therapeutic for those

found to be stage II and accurately directs further management. The combination of modern nerve-sparing techniques with a modified unilateral template means that this procedure can be performed without any long-term morbidity.

To conclude, it is perfectly reasonable to adopt nerve-sparing RPLND as the most appropriate management in early-stage cancer of the testis considering the current state of the art in clinical staging. Similarly, the results with nerve-sparing RPLND in the postchemotherapy setting are most encouraging; it is in this latter group that the nerve-sparing procedure may well have the greatest future potential.

SUMMARY

Currently, where available and widely practiced, nerve-sparing RPLND offers the least toxic and safest alternative in management of clinical stage I nerve-sparing germ cell tumor. Twenty-six percent to 30% of such cases are found to be node positive and, if no adjuvant chemotherapy is elected, two thirds do not relapse; those who do are uniformly rescued by chemotherapy. The 70% who are node negative have no long-term toxicity and do better in quality of life studies than their surveillance counterparts.¹ Also, risk-benefit and cost-benefit studies support the competitive position of RPLND vis-à-vis the other options.² Nonetheless, it is fair to say there are several options for management of clinical stage I nonseminomatous germ cell tumors that, when well applied, work well. Their choice depends on regional factors related to availability and experience.

References

1. Aass N, Grunfeld B, Kaalhus O, et al: Pre- and post-treatment sexual life in testicular cancer patients: A descriptive investigation. *Br J Cancer* 67:1113, 1993
2. Baniel J, Roth B, Foster R, et al: Cost and risk benefit considerations in the management of clinical stage I nonseminomatous testicular tumors. *Ann Surg Oncol* 3:86, 1996
3. Colleselli K, Poisel S, Schachtner W, et al: Nerve preserving bilateral retroperitoneal lymphadenectomy: Anatomical study and operative approach. *J Urol* 144:293, 1990
4. Donohue J: Retroperitoneal lymphadenectomy: The anterior approach including bilateral suprarenal hilar dissection. *Urol Clin North Am* 4:509, 1977
5. Donohue J, Rowland R: Complications of retroperitoneal lymphadenectomy. *J Urol* 125:338, 1981

6. Donohue J, Rowland R, Bihrl R: Transabdominal retroperitoneal lymph node dissection in diagnosis and management of genitourinary cancer. *In* Skinner DG, Lieskowsky G (eds): Genitourinary Cancer. Philadelphia, WB Saunders, 1988, p 802
7. Donohue J, Zachary J, Maynard S: Distribution of nodal metastases in nonseminomatous testicular cancer. *J Urol* 128:315, 1982
8. Einhorn L, Donohue J: Improved chemotherapy in disseminated testicular cancer. *J Urol* 117:65, 1977
9. Freedman L, Jones W, Peckham M, et al: Histopathology in the prediction of relapse of patients with stage I testicular teratoma treated by orchidectomy alone. *Lancet* 294:7, 1987
10. Hoskin P, Dilly S, Easton D, et al: Prognostic factors in stage I nonseminomatous germ cell testicular tumors managed by orchidectomy and surveillance: Implications for adjuvant chemotherapy. *J Clin Oncol* 4:1031, 1986
11. Jewett M, et al: Retroperitoneal lymphadenectomy for testicular tumor with nerve sparing for ejaculation. *J Urol* 139:1220, 1988
12. Lange P, Chang W, Fraley E: Fertility issues in the therapy of nonseminomatous testicular tumors. *Urol Clin North Am* 14:731, 1987
13. Narayan P, Lang P, Fraley E: Ejaculation and fertility after extended retroperitoneal lymph node dissection for testicular cancer. *World J Urol* 127:685, 1982
14. Pizzocaro G, Salvioni R, Zononi F: Unilateral lymphadenectomy in intraoperative stage I nonseminomatous germinal testis cancer. *J Urol* 134:485, 1985
15. Ray B, Hajdu S, Whitmore W: Distribution of retroperitoneal lymph node metastases in testicular germinal tumors. *Cancer* 33:340, 1974
16. Richie J, Garnick M: Modified retroperitoneal lymphadenectomy for patients with clinical stage I testicular tumor. *J Urol* 137:212, 1987

Address reprint requests to

Richard S. Foster, MD
Department of Urology: Indiana University Medical Center
535 North Barnhill Drive, Suite 420
Indianapolis, IN